

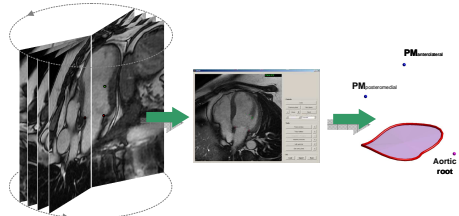
Feasibility of a Novel Approach for 3D Mitral Valve Quantification from Magnetic Resonance Images

Maffessanti F, Stevanella M, Votta E, Lombardi M, Parodi O, De Marchi D, Conti CA, Redaelli A, Caiani EG

Department of Biomedical Engineering, Politecnico di Milano
Milan, Italy

Mitral annulus (MA) assessment is of great importance for the diagnosis and treatment of mitral valve (MV) disease. Standard CMR image acquisition allows to obtain only a limited number of measurements. We propose a different way to study the MV by multiple CMR long-axis cine images, followed by 3D reconstruction and quantification. Our aim was to test the reproducibility of this approach.

CMR cine imaging of 18 long-axis planes (55 frames/cardiac cycle; spatial resolution: 0.78 mm; slice thickness: 8mm), rotated every 10° along the left ventricular long-axis, was performed in 12 patients with myocardial infarction. Custom software was used for MV quantitative analysis (Figure): 1) in the end-diastolic (ED) and end-systolic (ES) frames, in each plane, the position of the MA annulus and papillary muscles (PM) tips were manually identified; 2) the MA geometry and PM position were automatically reconstructed in a 3D space; 3) several parameters were then computed: MA perimeter, antero-posterior and intercommissural diameters, MA height, MA 3D and projected area, the angle between PM, the distance from PM to the MA. To assess the reproducibility of the procedure, two operators repeated the analysis: the inter-operator variability was evaluated as the coefficient of variation ($CV(\%)=100*SD/mean$).



Schematic of the workflow

Analysis of MA was feasible in all patients, showing good inter-operator agreement for MA perimeter ($CV_{ED}=1.9\%$; $CV_{ES}=1.8\%$), antero-posterior ($CV_{ED}=3.0\%$; $CV_{ES}=5.8\%$) and intercommissural diameters ($CV_{ED}=1.8\%$; $CV_{ES}=2.0\%$), 3D ($CV_{ED}=3.4\%$; $CV_{ES}=4.3\%$) and projected areas ($CV_{ED}=2.8\%$; $CV_{ES}=3.7\%$), and the distance from PM and MA ($CV_{ED}=4.1\%$; $CV_{ES}=4.6\%$). MA height ($CV_{ED}=9.9\%$; $CV_{ES}=16.1\%$) and the angle between PM ($CV_{ED}=6.8\%$; $CV_{ES}=10.6\%$) were less reproducible, in particular at ES.

Quantitative information on MA and PM morphology and function is feasible from CMR imaging n multiple long-axis planes. The proposed approach is highly reproducible and could constitute the basis for in-depth evaluation of the MV and for the planning of surgical procedures.