Characterization of Pulmonary Hypertension using Right Ventricular Regional Curvedness derived from CMR imaging

S.K. Teo[1], X.D. Zhao[2], R.S. Tan[2,3], L. Zhong[2,3], Y. Su[1]

[1]Institute of High Performance of Computing, A*STAR, Singapore
[2]National Heart Centre, Singapore
[3]Duke-NUS Graduate Medical School, Singapore

Pulmonary hypertension (PH) is one of the causes of right ventricle (RV) dysfunction due to pressure overload. The increased pulmonary arterial pressure leads to RV dilation through myocardial hypertrophy and subsequent contractile dysfunction. In this study, we proposed using geometry derived curvedness index at the end-systole (C_{ES}) phase computed from cardiac magnetic resonance (CMR) imaging to characterize PH patients. 23 normal controls and 23 PH patients that are age- and sex-matched were prospectively enrolled in this study. All participants underwent CMR imaging and the 3D RV geometry were reconstructed in the form of a triangulated surface mesh partitioned into 13 segments from the manually segmented short-axis contours based on our previous works. The curvedness for each RV segment is then computed by aggregating the curvedness from individual points in the segment. The advantages of our approach are that the computation of the RV curvedness is automated and reproducible for a given set of input contours.

Our preliminary results are as follows: There is a significant difference in C_{ES} for free-wall segments across the basal, mid and apical regions for the PH and control groups ($p < 0.05$). For the mid region, the mean C_{ES} for free-wall segments for PH patients in New York Heart Association (NYHA) class 2 is significantly different as compared to the control group (p-value < 0.05, 1-way ANOVA). Similarly, for the apical region, the mean C_{ES} for free-wall segments in PH patients in NYHA class 2 and 3 are also significantly different as compared to the control group (p-value < 0.05, 1-way ANOVA). Our results suggest that C_{ES} may potentially be used for correlating to the NYHA functional class for PH patients. Future work will include expanding the sample size of the patient group to further validate our results.

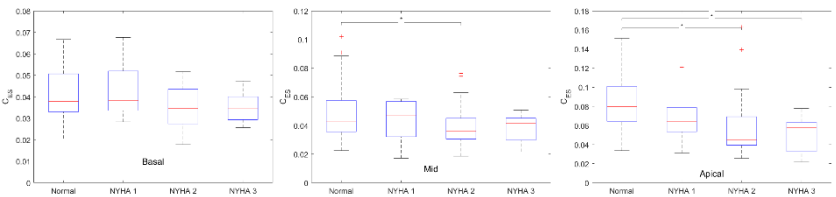

Box-whisker plot correlating C_{ES} for free-wall segments with the NYHA class (*p < 0.05)