Reconstruction of Patient-Specific Left Atrium Geometry from CMR imaging

S.K. Teo[1], X.D. Zhao[2], R.S. Tan[2,3], L. Zhong[2,3], Y. Su[1]

[1]Institute of High Performance of Computing, A*STAR, Singapore
[2]National Heart Centre, Singapore
[3]Duke-NUS Graduate Medical School, Singapore

Left atrial (LA) dilatation has been associated with a large variety of cardiac diseases and results from either the chronic volume and/or pressure overload of the LA. Studies have shown that LA dilation has been associated with the severity of left ventricular (LV) diastolic dysfunction and it is also a recognized adverse prognostic marker in several cardiac diseases. Currently, clinical quantification of LA volumes is performed using either the biplane area-length method or the method of discs (Simpson's method) on 2-D echocardiography images. However, these methods tend to underestimate LA volumes as compared to cardiovascular magnetic resonance (CMR) imaging. However, measuring LA volume from CMR using the above methods is time-consuming as it requires the acquisition of additional images and additional analysis time.

In this paper, we propose a geometry-based reconstruction algorithm for computing the LA volume automatically for the entire cardiac cycle by combining information from both the short- and long-axis from CMR imaging. The inputs to our reconstruction algorithm are as follows: (i) a set of segmented short-axis contours and (ii) a set of segmented long-axis contours from the standard 2-chamber and 4-chamber views. Our approach consists of a series of iterative steps where the most basal short-axis contour is projected in the LA direction and subsequently morph to the patient-specific LA shape using the long-axis contours as guide. These series of morphing generate a left heart comprising both the LV and LA geometries with a planar basal surface. To reconstruct the LA cap, this planar basal surface is morphed into a hemisphere representing the closed surface of the LA using the long-axis contours as guide, thereby allowing us to reconstruct the closed LA shape and to calculate its volume.

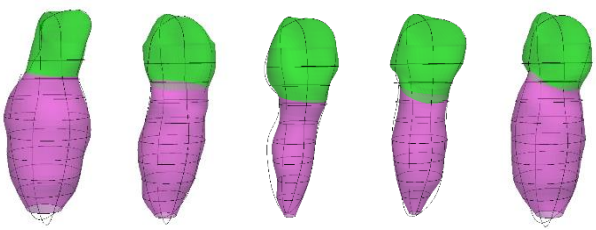

Selected instances of the LA (green) and LV (pink) geometries over the cardiac cycle for one subject. End-diastole frame: 1st panel. End-systole frame: 3rd panel.