Development of a New Approach for the Assessment of Complex Blood Flow Patterns in the Left Atrium from 4D Flow MRI

Enrico Soldati[1], Thomas Dietenbeck[2], Alban Redheuil[3], Alessandro Masci[1], Sophia Houriez[2], Gombaud Saintonge[2], Nadjia Kachenoura[2], Cristiana Corsi[1]

[1]DEI, University of Bologna, Campus of Cesena, Bologna, Italy
[2]LiB, University of Pierre et Marie Curie, Sorbonne University, Paris, France
[3]Department of Cardiology, Hôpital de la Pitié et Salpetriére, Paris, France

Introduction. The morphological and functional remodeling of the left atrium (LA) caused by mitral valve regurgitation (MVR) favours blood stasis and stroke risk. In this context, several clinical studies suggest that stoke risk stratification could be improved by using anatomical, morphological and hemodynamic information on the LA. The aim of this study was therefore to develop a new approach for the assessment of complex blood flow patterns in the LA using 4D Flow MRI images. **Methods.** Cardiac 4D flow MRI images were acquired in two patients affected by MVR and two healthy volunteers. 4D flow MRI data were first processed to extract the 3D LA anatomical models by applying the approach proposed by Chan and Vese. Velocities within the LA chamber were directly obtained by masking the 4D flow MRI using the anatomical model and kinetic energy was also computed in the same volume of interest. LA volume-time curve, velocity as well as kinetic energy information in correspondence of the S-, A- and E-wave were compared between MVR patients and healthy volunteers.**Results.** LA volumes in healthy volunteers were bigger compared to MVR patients as a consequence of a blood overload within the LA chamber. Overall, velocities inside the LA in MVR patients were lower than blood velocities in healthy volunteers. During the S-wave, in healthy volunteers higher velocities were localized near the pulmonary veins, while for MVR patients high velocities were also present in proximity of the MV caused by the regurgitant flow. This result was confirmed by the KE analysis showing that backflows occur in the LA during ventricular systole.

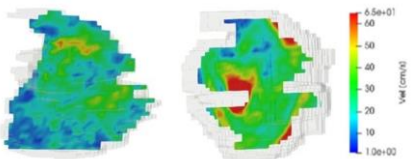

Conclusions. We developed a new approach for the analysis of a patient-specific model of atrial hemodynamics that is suitable for both healthy and MVR patients. Our analysis confirmed that MVR patients MVR show anatomical, morphological and hemodynamical changes that may reduce the washout of the LA chamber compared to the healthy group, which may lead to an increase of clot formation with a following increase of the risk of thromboembolism.