P-wave Analysis in Atrial Fibrillation Detection using a Neural Network Clustering Algorithm

Reza Firoozabadi*, Richard E. Gregg, Saeed Babaeizadeh
Advanced Algorithm Research Center, Philips Healthcare, Andover, MA, USA

Background: Absence of P-waves in ECG records with irregular interbeat intervals (R-R) is a sign of Atrial Fibrillation (AFib). Detection of P-waves in ECG beats or even templates could be challenging if the artifact resembles a P-wave, or an actual P-wave is buried in the artifact.

Method: We developed a neural network algorithm to generate the ECG beat clusters in segments of the record. Beats with matching QRS complexes were clustered using Self-Organizing Maps (SOM) and then cross-correlated to combine and generate the dominant template and subordinate templates. Artifact-corrupted and abnormal beats were isolated and eliminated in this process. Fiducial points of the dominant template were measured by morphological techniques. In the presence of a template P-wave, a search window is defined for individual beats in that template to exclude the potentially false P-waves. Our algorithm detects the presence or absence of the P-waves and measures several P-wave parameters. Variation of these parameters throughout a segment is the measure of presence of P-wave.

Results: Our algorithm was executed on ECG records in PhysioNet MIT-BIH Arrhythmia database with annotated normal and AFib rhythms (n=48), split into 1,951 segments of 30-second length (1,735 normal, 216 AFib) with 60,049 beats (52,322 normal, 7,727 AFib). Higher variation is observed in P-wave parameters of AFib segments. A 10-fold cross validation classifier with 100 iterations using the standard deviation of P-wave parameters including PR interval, P-peak, P-end, and P-wave peak to onset height, as well as the interbeat interval irregularities, resulted in AFib detection with average classification loss of 1.6%. Figure 1 shows the distribution of standard deviation of P-wave parameters and R-R interval.

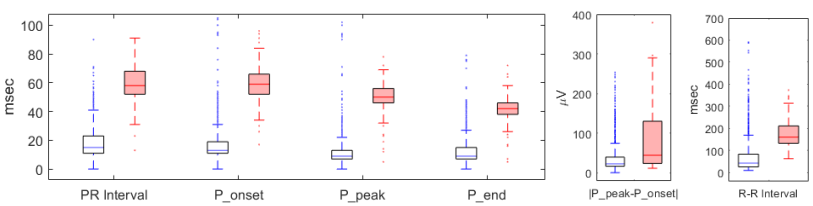

Figure 1. Distribution of standard deviation of P-wave parameters and R-R interval in normal rhythm (blank) and AFib (filled) segments.

Conclusions: Higher variation of P-wave parameters in an ECG segment with AFib rhythm, along with the irregularity in R-R intervals, led us to an AFib classification algorithm with low loss. ECG templates generated by our neural network algorithm helped us to exclude the abnormal or artifact-corrupted beats and find appropriate P-wave search windows.