

Volumetric Quantification of Myocardial Perfusion Using Analysis of Multi-Detector Computed Tomography 3D Datasets

N Kachenoura¹, F Veronesi², JA Lodato¹, C Corsi², R Mehta¹,
B Newby¹, RM Lang¹, V Mor-Avi¹

¹University of Chicago, Chicago, IL, USA
²DEIS, University of Bologna, Bologna, Italy

Abstract

Multi-detector computed tomography (MDCT) assessment of myocardial perfusion is based on visualization of 2D slices. To overcome the subjective nature of this analysis, we developed a new technique for quantification of myocardial perfusion from MDCT 3D datasets and tested it against nuclear myocardial perfusion imaging (MPI). MDCT datasets of 44 patients were analyzed to generate bull's eye display of myocardial perfusion and calculate segmental quantitative indices of extent and severity of perfusion defect. Visual interpretation of MDCT-derived bull's eyes was in agreement with rest MPI scores ($\kappa=0.79$). Quantitative MDCT perfusion data were in good agreement with MPI summed scores: $r=0.84$; objective detection of perfusion defects using MDCT index resulted in: area under ROC curve=0.87, sensitivity 0.92, specificity 0.91, and accuracy 0.89. Our technique for volumetric analysis of MDCT data allows accurate and objective detection of perfusion defects.

1. Introduction

While MDCT is increasingly used as an alternative to invasive coronary angiography, recent studies have demonstrated its potential to provide perfusion information, which could be a valuable addition in the diagnosis of coronary artery disease (CAD). These studies reported hypoenhanced areas corresponding to scar visualized in patients post myocardial infarction (MI), and in animals with acute MI [1]. However, the visualization of these areas is operator-dependent, as it requires adjustment of contrast. Also, the use of selected 2D slices is associated with the risk of missing small defects. A stumbling block in the quantification of MDCT perfusion is the inter-subject differences in myocardial enhancement that are related to body habitus, cardiac output, contrast dose and infusion rate, as well as segmental differences related to anatomic location [2].

We recently developed a new quantitative index of perfusion that was designed to take into account these differences, and tested it on 2D slices. The addition of this analysis improved the diagnostic accuracy of MDCT evaluation of CAD, especially in patients with high calcium scores and stents [3,4]. In the current study, we hypothesized that our adaptive technique for quantification of myocardial perfusion could be extended into volumetric analysis. Accordingly, our goals were: (1) to develop software for volumetric analysis of myocardial perfusion from MDCT 3D datasets, and (2) to test its ability to accurately determine the presence, location, extent and severity of perfusion abnormalities in agreement with SPECT MPI. To achieve the latter aim, we separately compared against MPI scores the results of visual analysis of bull's eye displays generated from MDCT data and a quantitative volumetric MDCT index of severity and extent of perfusion defect. This new quantitative index was also used to test the feasibility of objective detection of perfusion abnormalities.

2. Methods

We studied 44 patients who underwent CT coronary angiography (CTCA) for the evaluation of CAD. These patients were divided into a study group of 29 patients (age: 62 ± 10 , 23 males) who also had MPI within 57 ± 72 days (14 patient with normal MPI both at rest and stress and 15 patients with perfusion defects on MPI), and a control group of 15 patients (age: 58 ± 16 , 8 males) who had normal MPI both at rest and stress and no significant stenosis on CTCA. Patients who underwent coronary interventions between MPI and CTCA were excluded.

2.1. MDCT imaging

All CTCA studies were clinically indicated and performed according to a standard protocol. Images were obtained using an MDCT scanner (64-channels, Philips) with retrospective ECG-gating. A nonionic iodinated contrast agent was used (40-80 ml iv at 5-6 ml/sec).

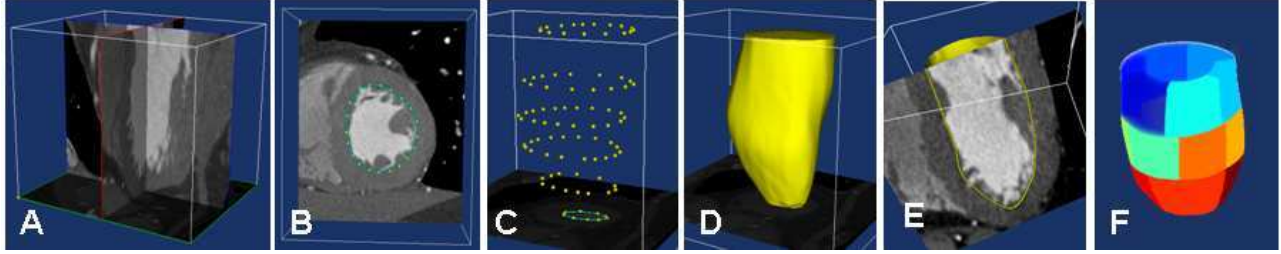


Figure 1. Example of MDCT dataset of the left ventricle depicting the steps of semi-automated volumetric myocardial segmentation

2.2. Myocardial segmentation

For each patient, the phase of the cardiac cycle used for CTCA was analyzed for perfusion. To allow the identification of left ventricular (LV) myocardium in 3D space (figure 1), both endocardial (figure 1B) and epicardial boundaries were manually initialized in 5 to 6 slices. Following initialization, both endocardial and epicardial surfaces were estimated using the level-set technique [5], and displayed using 3D rendering (figure 1D), which could be sliced in any arbitrary plane (figure 1E) to allow verification and, when necessary, correction of the initial boundaries. The LV myocardium was divided into 16 segments, according to standard AHA segmentation (figure 1F). To assign each segment to a specific artery, coronary anatomy depicted on individual MDCT volume rendering of the heart was used to determine the perfusion territory of each artery.

2.3. MDCT bull's eye display

Figure 2 shows how the MDCT bull's eyes were generated. For each short-axis slice, mean myocardial attenuation normalized by mean LV cavity attenuation was calculated along radial profiles (figure 2A). Value calculated from each profile and corrected to take into account segmental heterogeneity, was used to populate a single pixel in the bull's eye (figure 2B), with the distance from the origin corresponding to slice distance from the apical tip. Then values of the 2D bull's eye were expressed in percent of the maximum value, and a median filter was used to smooth the display. The color scale of the bull's eye was matched to that used for MPI data (figure 2C). These bull's eyes were reviewed by an experienced nuclear cardiologist blinded to MPI data, and segmental perfusion was graded using MPI scale: 0-normal, 1-borderline, 2-mild, 3-moderate and 4-severe.

2.4. Quantification of perfusion defects

In each myocardial segment, severity and extent of perfusion defect were quantified from histograms of x-ray attenuation. The segment with the highest mean value was used as a reference for normal myocardial distribution. The reference histogram was normalized to

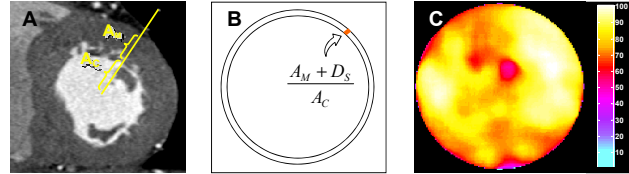


Figure 2. Schematic of the construction of the bull's eye display from MDCT 3D datasets.

have the same amplitude as that of the current segment. Then, to take into account the regional heterogeneity in x-ray attenuation, the normalized reference was shifted by the difference between the mean attenuation values, in the two corresponding segments, obtained in the control 15 patients (figure 3, left). Figure 3 (right) shows histograms of a segment with abnormal attenuation (blue) and the reference histogram before (dashed black) and after the shift (solid black). The adjusted reference (solid black) was then subtracted from the histogram of the current segment (blue). The area S under the difference curve (red) that did not overlap with the adjusted reference, represented the excess of voxels with low attenuation, and was thus related to the extent of hypo-enhancement. This number of voxels, S , was expressed in percent of the total volume of the current segment, resulting in a segmental relative volume of the defect:

$$Defect\ volume(\%) = 100 \cdot \frac{S}{segment\ volume}$$

The severity of the defect was estimated by the distance between the peak of the adjusted reference histogram and that of the difference curve, which was normalized by the mean intensity in the LV cavity attenuation to allow comparisons between patients:

$$Defect\ severity = \frac{\Delta A}{mean\ LV\ cavity\ attenuation}$$

Finally, the product of these two parameters was used as a segmental quantitative index that combines extent and severity of hypo-enhancement, Q_H .

2.5. Statistical analysis

First, agreement between segmental grades obtained from the visual analysis of MDCT and MPI bulls' eyes was estimated using kappa statistics on a segment, coronary territory and patient basis.

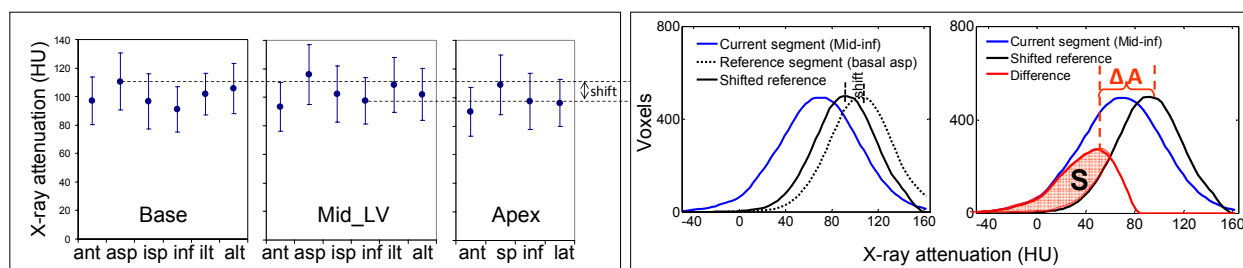


Figure 3. Quantification of extent and severity of myocardial hypo-enhancement, see text for details.

Then, the agreement between MDCT myocardial perfusion and rest MPI data was studied quantitatively: (1) summed segmental Q_H values were correlated with summed segmental rest MPI scores on a coronary territory and a patient basis; (2) ROC analysis was performed using MPI segment classification as normal or abnormal as a reference (grade >0 is abnormal) to test the feasibility of objective detection of perfusion defects using the Q_H index. Sensitivity and specificity of this detection with the optimal Q_H threshold were estimated on a vascular territory, and patient basis. To this effect, a coronary artery was considered abnormal when ≥ 2 contiguous abnormal myocardial segments were detected in that territory, and a patient was considered abnormal when at least one abnormal territory was present. For every comparison, sensitivity, specificity, positive and negative predictive values (PPV, NPV) and overall accuracy were calculated.

3. Results

In the study group, MPI detected perfusion abnormalities in 15/29 (52%) patients, including 4 with single-vessel disease, 6 with two-vessel disease and 5 with triple-vessel disease. These abnormalities were noted in 31 coronary territories, of which the defects were fully reversible (not present at rest) in 6 territories.

3.1. Qualitative comparisons

Figure 4 shows examples of MDCT (top) and MPI (bottom) bull's eyes obtained in two patients with and without CAD. These images demonstrate that the two techniques closely agreed in these patients in terms of presence and location of perfusion defects.

The two techniques yielded absolute agreement (identical scores) in 363/464 (78%) segments, while difference of no more than 1 grade was noted in 428/464 segments (92%), corresponding to $\kappa=0.71$, reflecting good agreement. The comparison between visual interpretation of MDCT bulls' eyes and rest MPI classification as normal or abnormal resulted in $\kappa=0.70$ by coronary territory and in $\kappa=0.79$ by patient, supporting the good agreement between the two techniques.

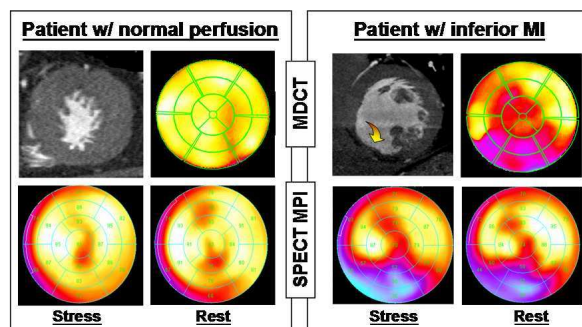


Figure 4. Bull's eye display of myocardial perfusion obtained in a patient with normal perfusion and a patient with inferior MI.

3.2. Quantitative comparisons

Figure 5 shows the results of linear regression analysis between Q_H and rest MPI scores, both summed over all segments in each coronary territory and in each patient.

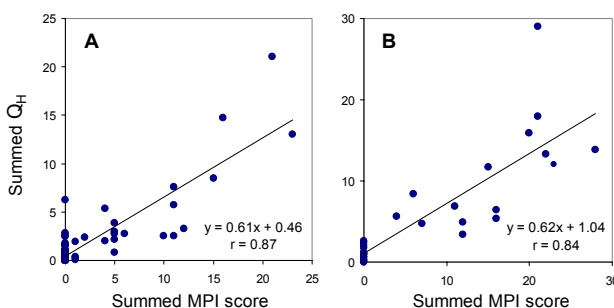


Figure 5. Linear regression analysis between the quantitative index, Q_H , and rest MPI scores, in a coronary territory basis (A), and in a patient basis (B).

ROC analysis for objective detection of perfusion abnormalities using segmental index Q_H against rest MPI reference resulted in $AUC=0.87$. The threshold value of $Q_H=0.263$ allowed optimal classification of segments as normal or abnormal, resulting in levels of agreement that are summarized in Table 1, by segment, coronary territory and by patient. Overall, high levels of agreement were obtained.

	Segment	Territory	Patient
Sensitivity	0.79	0.78	0.92
Specificity	0.83	0.91	0.86
PPV	0.50	0.78	0.86
NPV	0.95	0.91	0.92
Accuracy	0.83	0.88	0.89

Table 1. Agreement between objective MDCT-based detection of perfusion abnormalities and rest MPI reference.

4. Discussion and conclusions

This is the first study to validate 3D analysis of MDCT myocardial perfusion against a SPECT MPI reference technique. Our primary goal was to test the hypothesis that: volumetric analysis of MDCT images would allow accurate detection of myocardial perfusion abnormalities.

The unique features of our new technique include its adaptive character designed to take into account the heterogeneity in x-ray attenuation due to anatomic location [2] by using the data obtained in the control group. In addition, inter-patient contrast differences were addressed by normalizing by the x-ray attenuation in the LV cavity. Moreover, the quantitative and volumetric nature of our technique overcomes the need for subjective and time-consuming selection of 2D slices. Importantly, our 3D approach provides quantitative estimates of the defects volume, a variable with known prognostic value. With these advantages over the existing 2D methodology and its ease of use and speed of analysis (Analysis of a single dataset required approximately 10 minutes), our approach is poised to become an integral part of analysis in future studies of MDCT perfusion during stress testing, which is an area of growing interest [6].

The detection of perfusion defects was achieved using two different approaches: (1) a visual interpretation of the MDCT-derived bull's eyes display, familiar to cardiologists, and (2) an objective, volumetric measure of extent and severity of perfusion abnormality.

The quantitative analysis resulted in high correlation with rest MPI summed scores (figure 5) and the objective classification of myocardial segments as normal or abnormal was found to be accurate, as reflected by high area under ROC curve value and high levels of agreement with the reference technique (Table 1).

A limitation of our technique is that the adaptive approach relies on the availability of normal values which in this study were obtained in a relative small control group. However, the main goal of this study was to develop a new method and test its feasibility for volumetric quantification of myocardial perfusion and detection of fixed perfusion defects. Future studies in a larger population of unselected patients with a wide range of perfusion abnormalities, including stress-induced ischemia in patients with intermediate grade stenosis, are necessary to validate this methodology.

In conclusion, we developed a new technique for volumetric analysis of myocardial perfusion from MDCT images, and demonstrated its ability to accurately determine the presence, location, extent and severity of perfusion abnormalities in agreement with MPI. Because perfusion information may aid in elucidating the clinical significance of coronary lesions, especially in patients with intermediate grade coronary stenosis, and because the ability of CTCA to evaluate CAD is known to be affected by calcium and stents, the addition of perfusion information may improve the accuracy of cardiac CT in the diagnosis and evaluation of CAD. Importantly, the use of MDCT data acquired for CTCA provides this potentially clinically useful information without additional radiation or contrast load.

References

- [1] Gerber BL, Belge B, Legros GJ, Lim P, Poncelet A, Pasquet A, Gisellu G, Coche E, Vanoverschelde JL: Characterization of acute and chronic myocardial infarcts by MDCT: comparison with contrast-enhanced magnetic resonance. *Circulation* 2006;113:823-33
- [2] Boll DT, Merkle EM, Paulson EK, Hoffmann MH: Assessment of the myocardium on 2-phase cardiac multidetector computed tomography: does cyclic cardiac contraction influence myocardial attenuation? *J Comput Assist Tomogr* 2008;32:602-608
- [3] Kachenoura N, Gaspar T, Lodato JA, Bardo DME, Newby B, Gibbs S, Peled N, Lang RM, Mor-Avi V: Combined assessment of coronary anatomy and myocardial perfusion using multi-detector computed tomography for the evaluation of coronary artery disease: Validation against invasive coronary angiography. *Am J Cardiol* 2009 (in press, available online)
- [4] Kachenoura N, Lodato JA, Gaspar T, Bardo DME, Newby B, Gips S, Peled N, Lang RM, Mor-Avi V: Value of multi-detector computed tomography evaluation of myocardial perfusion in the assessment of ischemic heart disease: Comparison with nuclear perfusion imaging. *Eur Radiol* 2009 (in press, available online)
- [5] Corsi C, Lang RM, Veronesi F, Weinert L, Caiani EG, MacEneaney P, Lamberti C, Mor-Avi V: Volumetric quantification of global and regional left ventricular function from real-time three-dimensional echocardiographic images. *Circulation* 2005; 112:1161-1170
- [6] George RT, Silva C, Cordeiro MA, DiPaula A, Thompson DR, McCarthy WF, Ichihara T, Lima JA, Lardo AC: Multidetector computed tomography myocardial perfusion imaging during adenosine stress. *J Am Coll Cardiol* 2006; 48:153-160

Address for correspondence:

Victor Mor-Avi, PhD
 University of Chicago MC5084,
 5841 S. Maryland Ave., Chicago Illinois 60637.
 E-mail: vmoravi@medicine.bsd.uchicago.edu