

Feasibility of Atrial Activation Time Imaging

F Hanser^{1,2}, B Tilg¹, R Modre¹, G Fischer¹, B Messnarz^{1,2}, F Hintringer³, FX Roithinger³

¹Institute for Medical Signal Processing and Imaging,

University for Health Informatics and Technology Tyrol, Innsbruck, Austria

²Institute of Biomedical Engineering, Graz University of Technology, Austria

³Clinical Department of Cardiology, University Hospital Innsbruck, Austria

Abstract

The feasibility of atrial activation time imaging is investigated based on data sets of four patients who underwent an electrophysiologic study. Several pacing protocols with pacing sites at the right atrial appendage, coronary sinus, and high right atrium were part of the study and were employed to reconstruct the associated atrial activation time patterns. The localization error was estimated to be between 8 and 14 mm.

1. Introduction

Atrial and ventricular surface activation time imaging from body-surface ECG mapping data is supposed to become a diagnostically powerful clinical tool for assessing cardiac arrhythmias [1]. This cardiac source imaging technique aims at providing noninvasively information about electrical excitation in order to assist the cardiologist in developing strategies for the treatment of cardiac arrhythmias. Common cardiac arrhythmias, such as the Wolf-Parkinson-White syndrome, atrioventricular nodal reentrant tachycardia, or atrial fibrillation, can, at least in many cases, be traced back to accessory pathways, atrial or ventricular foci, e.g. from the pulmonary veins [2, 3], and reentrant circuits. Identifying the site of origin of the ectopic focus or the location of an accessory pathway provides the essential information for treatment strategies, such as catheter ablation [4].

Activation time imaging from 3D+time anatomical and body-surface ECG mapping data enables noninvasively the imaging of the electrical function in the heart [5]. The method yields solutions to the electrocardiographic inverse problem and is based on an electrodynamic model of the patient's volume conductor and heart. The model of the heart includes a model of both the atrium and ventricle. A separate model for the atrium and ventricle has been inevitable because whole heart models still resist a computational and technical implementation for providing solutions to the electrocardiographic inverse problem.

Atrial activation time imaging constitutes a more sophisticated problem with respect to ventricular activation time imaging. The complex geometry of the atria (orifices of the pulmonary veins, orifices of superior and inferior vena cava, tricuspid and mitral annuli, and right and left appendages) makes it more difficult to generate a geometrical model that qualifies for a boundary element formulation. The poor contrast in the MR images makes the segmentation process quite delicate. In addition, only the endocardial boundaries can be seen in the atrial MR images. Epicardial boundaries have, therefore, to be constructed artificially. A signal-to-noise ratio of about 20dB (more than 40dB in ventricular activation time imaging) and the significantly smaller effective rank of the ECG data matrix impose additional challenges on the stability of the inverse algorithm.

In this work we investigate the feasibility of atrial activation time imaging based on data sets of four patients who underwent an electrophysiologic study.

2. Data acquisition and modeling

Body-surface ECG data were acquired under clinical conditions with a 62-lead ECG mapping system. The Mark-8 body-surface potential mapping system (Biosemi V.O.F., The Netherlands) is an on-line portable computer acquisition system with data transmission via optical fiber. A radiotransparent carbon electrode array was utilized to record unipolar ECG signals from 62 torso sites (anterior 41, posterior 21) while simultaneously enabling X-ray examination. The Wilson Central Terminal defined, as usual, the reference potential [6]. Electrode signals were amplified and high-pass and low-pass filtered at edge frequencies of 0.3Hz and 400Hz with a first and fourth order analog Bessel filter, respectively. Analog-to-digital conversion was realized by a 16 bit AD converter at a sampling rate of 2048Hz per channel and a quantization resolution of 500nV/bit. No additional digital filtering was applied.

The torso was imaged with a 1.5Tesla MR scanner

(Siemens Vision Plus). The myocardium was additionally imaged in an ECG-gated breath-hold oblique imaging mode in order to model the heart's surface. Vitamin E markers were utilized to determine 7 reference positions from the axial MR scans to be able to couple MRI with ECG data. The 62 electrode and 7 reference positions were acquired with the FASTRAK system (Polhemus Inc., USA). The entire volume conductors including the blood masses were modeled with about 4100 triangles [7]. The atrial surfaces were represented by about 1050 triangular elements. The different individual compartments comprised the torso, the lungs, and the blood mass. The associated conductivities were assumed to be 0.2, 0.08, and 0.6Sm⁻¹, respectively. Figure 1 shows a geometrical representation of a patient's volume conductor together with electrode positions of the 62-lead ECG mapping system.

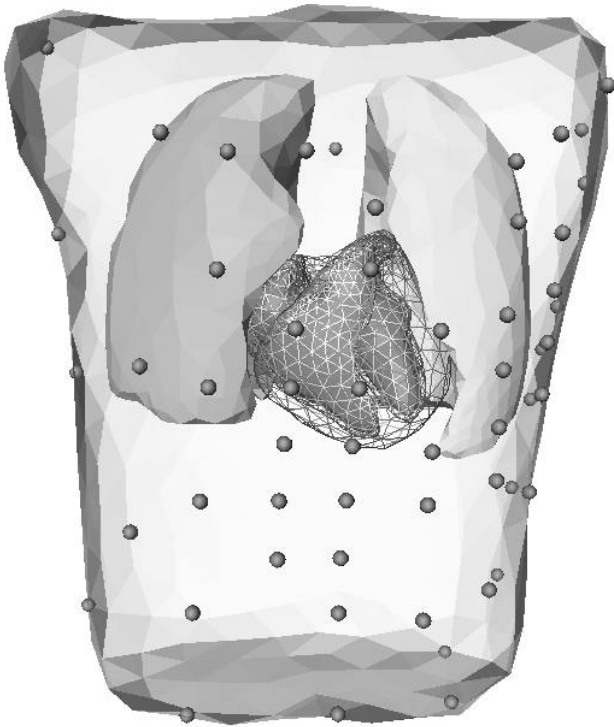


Figure 1. Geometrical model of an individual patient's torso. The model depicts all electro-dynamically relevant compartments: torso, lungs, and blood masses. Spheres indicate electrode positions of the 62-lead ECG mapping system.

3. Inverse method

Endocardial and epicardial activation time patterns were reconstructed by employing a method capable of providing solutions to the electrocardiographic inverse problem.

Mathematically speaking, the relation between activation time on the atrial surface and the body surface ECG is represented by a nonlinear inverse ill-posed problem. It can be formulated in the following form:

$$\mathcal{F}\tau = D, \quad (1)$$

where \mathcal{F} is a nonlinear operator which maps the activation time τ onto the body surface ECG data D . Assuming $\{\tau_k\}_{k=0}^{\infty}$ to be a series of approximations of the true solution τ and linearizing Eq. (1) in the point τ_k yields

$$\mathcal{F}\tau_k + \mathcal{F}_k(\tau - \tau_k) = D, \quad (2)$$

where \mathcal{F}_k is an abbreviation for $\mathcal{F}(\tau_k)$ and \mathcal{F} represents the Frechet derivative of the operator \mathcal{F} . Equation (1) can be written in a technically more useful form

$$\mathcal{F}_k\tau = D_k, \quad (3)$$

with $D_k = D + \mathcal{F}_k\tau_k - \mathcal{F}\tau_k$. Equation (3) is, in general, again ill-posed. In order to find a regularized approximation for τ a regularization method for linear ill-posed problems can be employed. Applying second order Tikhonov regularization with the Laplacian operator Δ and the regularization parameter λ_k yields the following regularized approximation

$$\tau = (\mathcal{F}_k^*\mathcal{F}_k + \lambda_k^2\Delta^*\Delta)^{-1}\mathcal{F}_k^*D_k, \quad (4)$$

where the asterisk marks the adjoint operator. Repeating this process yields an iteration process

$$\tau_{k+1} = \tau_k + \delta\tau_k, \quad (5)$$

with the incremental activation time

$$\delta\tau_k = (\mathcal{F}_k^*\mathcal{F}_k + \lambda_k^2\Delta^*\Delta)^{-1} \times \{\mathcal{F}_k^*(D - \mathcal{F}\tau_k) - \lambda_k^2\Delta^*\Delta\tau_k\}. \quad (6)$$

As the index k increases the iteration process in Eq. (5) converges to a regularized approximation of the activation time pattern τ . A more detailed description of the inverse method can be found in [1]. Additional information on issues related to the electrocardiographic inverse problem provides [8, 9, 10].

4. Results

Data sets of four patients were the basis for reconstructing atrial activation time patterns in order to investigate the feasibility of atrial activation time imaging. Figure 2 shows an endocardial sinus rhythm activation time map of a 24-year-old female patient having suffered from a WPW syndrome caused by an accessory pathway in the left atrium. The map indicates early activation somewhere in

the sinus node region and fast conduction to the left atrium via Bachmann's bundle. An invasive CARTO® map of the left atrium, not shown here, was available for this data set clearly supporting fast conduction via Bachmann's bundle. Figure 3 shows a reconstructed activation time

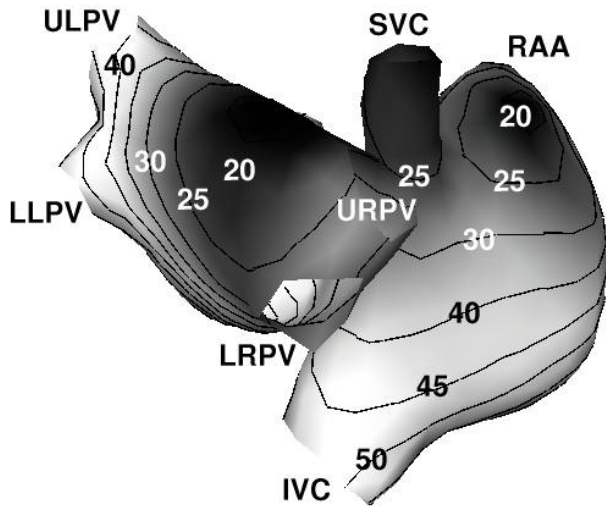


Figure 2. Endocardial sinus rhythm activation time map from a right posterior view showing early activation in the sinus node region and conduction via Bachmann's bundle. Isochrones indicate time steps of 5ms. Following abbreviations are used: superior vena cava (SVC), inferior vena cava (IVC), right atrial appendage (RAA), upper left pulmonary vein (ULPV), lower left pulmonary vein (LLPV), upper right pulmonary vein (URPV), lower right pulmonary vein (LRPV).

map of a 22-year-old male patient suffering again from a WPW syndrome. The patient's electrophysiologic study involved a pacing protocol with the pacing site somewhere in the lower right posterior atrium. The first endocardial breakthrough was clearly reconstructed. An activation time map of another right atrial pacing protocol shows Fig. 4. The catheter was positioned in the 22-year-old male patient's right atrial appendage. Again, the site of first endocardial breakthrough was clearly reconstructed to be somewhere in the right atrial appendage. The map also shows fast excitation of the left atrium via Bachmann's bundle. Figure 5 shows a reconstructed endocardial activation time map of a 61-year-old male patient suffering from atrial flutter and episodes of atrial fibrillation. Part of the patient's electrophysiologic study was a coronary sinus pacing protocol. The site of first endocardial breakthrough was reconstructed to be somewhere in the lower posterior left atrium clearly indicating the pacing site.

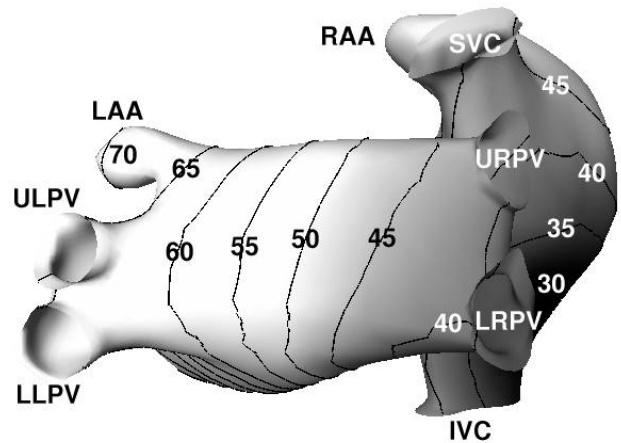


Figure 3. Right posterior lateral oblique view of an endocardial activation time map according to a pacing protocol with the lower right posterior region as pacing site. Isochrones are in steps of 5ms. Abbreviation LAA indicates left atrial appendage. Other abbreviations as in Fig. 2.

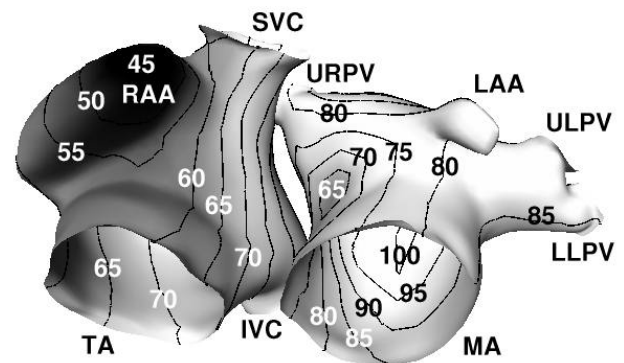


Figure 4. Left-lateral anterior view of an endocardial activation time map according to a pacing protocol with the right atrial appendage as pacing site. Isochrones are in steps of 5ms. Abbreviations TA and MA indicate tricuspid and mitral annulus, respectively. Other abbreviations as in figures above. Note excitation of left atrium via Bachmann's bundle.

5. Conclusion

This work demonstrated that atrial activation time imaging from paced and sinus rhythm ECG mapping data is feasible under clinical conditions. The localization accuracy of the paced rhythms was assessed to be between 8 and 14mm. The imaging of spontaneous rhythms, like the onset of atrial fibrillation or foci from the pulmonary veins, constitute a more sophisticated imaging task necessitating further improvement of the method. Based on our experience, the following aspects have to be

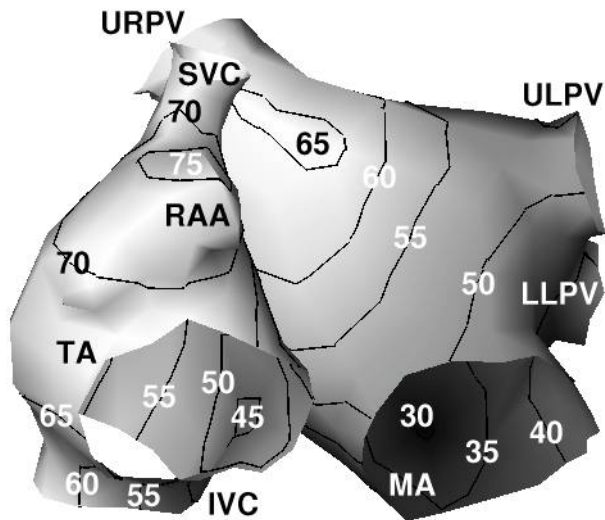


Figure 5. Endocardial activation time map of a coronary sinus pacing protocol. Abbreviations as in figures above.

considered with respect to atrial activation time imaging: firstly, and not surprisingly, an accurate geometrical model of the patient's atria is of utmost importance, because the atrial surfaces contain the electrical sources in our bidomain-based problem formulation. Secondly, the target ECG wave, selected for the imaging process, has to represent uniquely the underlying activation process. In clinical situations, however, atrial activity is often obscured by ventricular activity. Such a situation requires appropriate cancellation techniques. Thirdly, the employed inverse approach has to display the numerical performance in order to yield a unique and stable inverse solution in the presence of a noisy environment.

Acknowledgements

This work was supported by the START Y144-INF program funded by the Federal Ministry of Education, Science and Culture, Vienna, Austria.

References

- [1] Modre R, Tilg B, Fischer G, Wach P. An iterative algorithm for myocardial activation time imaging. *Comput Methods Programs Biomed* 2001;64:1–7.
- [2] Haissaguerre M, Jais P, Shah DC, Takahashi A, Hocini M, Quiniou G, Garrigue Le Mouroux A, Le Metayer P, Clementy J. Spontaneous initiation of atrial fibrillation by ectopic beats originating from the pulmonary veins. *N Engl J Med* 1998;9:659–666.
- [3] Chen SA, Hsieh MH, Tai CT, Tsai CF, Prakash VS, Yu WC, Hsu TL, Ding YA, Chang MS. Initiation of atrial fibrillation by ectopic beats originating from the pulmonary veins: electrophysiological responses, and effects of radiofrequency ablation. *Circulation* 1999;100:1879–1886.
- [4] Morady F. Radio-frequency ablation as treatment for cardiac arrhythmias. *N Engl J Med* 1999;340:534–544.
- [5] Tilg B, Fischer G, Modre R, Hanser F, Messnarz B, Schocke M, Kremser C, Berger T, Hintringer F, Roithinger FX. Model-based imaging of cardiac electrical excitation in humans. *IEEE Trans Med Imaging* 2002;21(9):217–226.
- [6] Fischer G, Tilg B, Modre R, Hanser F, Messnarz B, Wach P. On modeling the wilson terminal in the boundary and finite element method. *IEEE Trans Biomed Eng* 2002;49:217–224.
- [7] Fischer G, Tilg B, Modre R, Huiskamp GJM, Fetzer J, Rucker W, Wach P. A bidomain model based BEM–FEM coupling formulation for anisotropic cardiac tissue. *Ann Biomed Eng* 2000;28:1229–1243.
- [8] Greensite F. The mathematical basis for imaging cardiac electrical function. *Crit Rev Biomed Eng* 1994;22:347–399.
- [9] Huiskamp GJM, Greensite F. A new method for myocardial activation time imaging. *IEEE Trans Biomed Eng* 1997;44:433–446.
- [10] Rudy Y, Burnes JE. Noninvasive electrocardiographic imaging. *Ann Noninvasive Electrocardiol* 1999;4:340–359.

Address for correspondence:

Friedrich Hanser, PhD
 Institute of Biomedical Engineering
 Graz University of Technology
 Krenngasse 37 / A-8010 Graz / Austria
 tel./fax: ++43-316-873-5342 / 5340
 friedrich.hanser@tugraz.at